



**DATE PRESENTING CLINICAL SIGNS**

2.26.26 History: Presents for evaluation of weight loss. New grade 3/6 cardiac murmur PMI sternal. Elevated ProBNP. Newly diagnosed hyperthyroid. Azotemia. Assess prior to starting thyroid medication.

**PATIENT**

Maia Eberwein

-Pertinent abnormal PE/Chem/CBC/UA Results: CBC: WNL. Chemistry: SDMA: 17 (0 - 14), Creatinine: 2.4 (0.9 - 2.3), BUN: 57 (16 - 37), ALP: 64 (12 - 59), CK: 834 (64 -- 440), BNP: 705 (0 - 100). UA: USG 1.013, 2+ protein. T4: 5.3 (0.8 - 4.7). Azotemia appears iris stage 2 but concern for unmasking due to hyperthyroidism.

**SPECIES**

Feline

-CXR report: cardiomegaly. No CHF.  
-Current medications: None current.  
-Sedation used: Not required to complete full diagnostic ultrasound.  
-Pertinent previous ultrasound results: No previous.  
-STAT: Not requested.

**BREED**

-Imaging performed by: Stephanie Warga RDCS, RVT.

DSH

**SEX**

FS

**AGE**

1.14.15

**ECHOCARDIOGRAM FINDINGS**

2D, m-mode, color flow and doppler imaging is available. The left ventricular wall is normal in dimension. There is a mildly hyperechoic endocardium consistent with mild fibrosis. The papillary muscles are mildly enlarged and remodeled. The endocardium is remodeled. The left atrium is normal in size. The right atrium is normal in size. The right ventricle appears normal. The mitral valve is normal. No significant systolic anterior motion is seen; however, the LVOT velocity is mildly elevated. Mild MR. Mildly elevated velocity through the RVOT with a dynamic profile. Trace TR. Normal velocity. No AI or PI. No pleural or pericardial effusion seen. No obvious cardiac tumors.

**WEIGHT**

11.5lbs

**CARDIAC CHART**

**INTERPRETED BY**

Maggie Machen Lamy,  
DVM, DACVIM  
(Cardiology)

**HOSPITAL NAME**

Warm & Fuzzy VC

**REFERRING VET**

Dr. Miller

**INVOICE**

47015

FELINE CARDIAC PARAMETERS	BODY WEIGHT (kg)	HR (BPM)	IVSd (cm) (Moise, Pipers)	LVIDd (cm) (Moise, Pipers)	LVWd (cm) (Moise, Pipers)	FS (%)	EF (%)
<b>NORMAL PARAMETER</b>	-----	150-240	3.5-0.55	<2 (mean 1.5)	3.5-0.55	35-67	80-100
<b>PATIENT</b>	5.2	NM	0.45	1.5	0.50	60	90
FELINE CARDIAC PARAMETERS	LA/AO (Boon)	LA/AO HEART BASE (Swe) (Abbott)	LA 2D short axis Base view (cm) (Abbott)		LVOT VEL (m/s)	RVOT VEL (m/s)	E max (m/s)
<b>NORMAL</b>	<1.5	<1.3	<1.2		<1.6	<1.3	<0.9
<b>PATIENT</b>	NM	1.3	1.2		2.2	1.8	NM

Adapted from June Boon, Veterinary Echocardiography, 1998  
Abbott J & MacLean H JVIM 2006;20: 111-119, Moise et al. Am J Vet Res 47:1476, 1986. Pipers et al. Am J Vet Res 40:882, 1979.

### **INTERPRETATION OF THE FINDINGS & FURTHER RECOMMENDATIONS**

Mild abnormalities are identified in this study. The murmur appears to be due to a combination of a dynamic LVOT and RVOT obstruction. A progressive LVOTO would be a concerning development going forward and monitoring is advised as this may be the first sign of HOCM. At this time however, the LV wall thickness is normal with no evidence of hypertrophic disease. These findings can also develop secondary to hyperthyroidism and/or volume depletion. Both which are likely contributing in this case. There is no evidence of elevated left atrial pressure indicating low risk for complications at this time. No additional issues are identified. A BP is recommended.

Given these findings, no medications are indicated. Further addressing systemic issues is recommended, as these are the likely cause of BNP elevation.

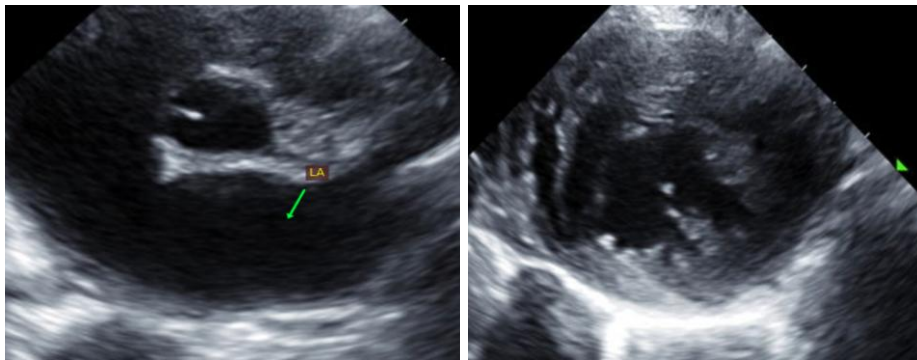
Prognosis is guarded until progression is assessed.

Monitor for any clinical evidence of cardiac compromise, including respiratory changes and/or signs of a blood clot event (paralysis, neurologic changes, etc.).

Anesthetic risk is considered mild, however judicious IV fluid rates are advised to avoid fluid overload. Additionally, drugs that stimulate heart rate should be avoided unless clinically necessary (glycopyrrolate, atropine). Avoid vasodilators as this may worsen the obstruction. A reasonable protocol includes opioid/benzodiazepine premedication, propofol induction, and isoflurane maintenance. Additionally, steroids should be used with caution on older cats, as even a 'normal' geriatric heart can develop evidence of intolerance and fluid retention.

Recommend recheck echocardiogram in 6-12 months.

### **IMAGES**



**The information and recommendations provided are based on the images presented by the referring veterinarian. No evaluation can be communicated regarding pathology that was not visible in the image/video clips provided.**

Thank you for this referral. This report was generated using transcription software, and minor dictation errors may be present. If the clinical or image interpretation does not parallel your findings or if I can be of

any further assistance, please contact me.

**Maggie Machen Lamy, DVM**  
**Diplomate of the American College of Veterinary Internal Medicine (Cardiology)**  
**info@sonopath.com**